

## **A NOVEL APPROACH FOR DETECTION OF GLAUCOMA USING FUNDUS IMAGES**

**<sup>1</sup>Dr.P.Sreenivasulu,**

<sup>1</sup> Professor, Department of ECE, Narayana Engineering College, Gudur, AP, 524101  
Email :<sup>1</sup>vardhan.sreenivasulu@gmail.com,

**<sup>2</sup>V.Sai Rama Sushma Priya, <sup>2</sup>S.Kalpana, <sup>2</sup>Ch.Lavanya, <sup>2</sup>P.Pavan Kalyan**

<sup>2</sup>UG Student, Department of ECE, Narayana Engineering College, Gudur, AP, 524101  
<sup>2</sup>vsrsp241298@gmail.com

**Abstract:** Glaucoma is one of the leading cause of blindness worldwide. A common eye condition in which the fluid pressure inside the eye rises to a level higher than healthy for that eye. The detection and diagnosis of glaucoma is very important. If untreated, it may damage the optic nerve, causing the loss of vision or even blindness. This is called Glaucoma, it is often called “silent thief of sight” as it has no symptoms and if not detected at an early stage it may cause permanent blindness. Glaucoma progression precedes some structural changes in the retina which aid ophthalmologists to detect glaucoma at an early stage and stop its progression. Fundoscopy is among one of the biomedical imaging techniques to analyse the internal structure of retina. Automatic analysis of retina images is becoming an important screening tool now days. This technique helps to detect various kind of risks and diseases of eyes. Glaucoma increases the cup to disc ratio (CDR), affecting the peripheral vision loss. This paper addresses the various image processing techniques to diagnose the glaucoma based on the CDR evaluation of pre-processed fundus images. These algorithms are tested on publicly available fundus images and the results are compared. Our proposed technique provides a novel algorithm to detect glaucoma from digital fundus image using a hybrid feature set. We will analyses the symptoms shown by different patients and compute and generalize them to reach a decision. This will help not only patients but doctors also to make it primarily practice to follow for new patients We propose a novel combination of structural (cup to disc ratio) to improve the accuracy of automated diagnosis of glaucoma. This technique is almost 95-97% successfully used to detect glaucoma comparatively very low cost rather than the conventional technique.

**Keyword:** *About Glaucoma, Automatic Glaucoma detection, technique, Fundoscopy.*

### **1.INTRODUCTION**

Glaucoma is a disorder of optic system characterized by the progressive degeneration of optic nerve fibres. Due to its lack of symptoms in its developing stages, and concurrent irreversibility once heavy vision loss is detected, early detection of glaucoma is highly desirable if blindness is to be avoided. While there has been work done on predicting glaucoma from other retinal image such as using structural and non-structural features. Typically, vision loss occurs from changes in the intraocular eye pressure due to blockages that prevent the circulation of aqueous fluid in the eye or from problems involving the optic nerves themselves (blood supply, structure of the nerve, etc.) [5]. There are many methods to detect glaucoma exist; Open angle glaucoma (OAG) is a slowly progressive atrophy of the optic nerve, characterized by loss of peripheral visual function and an excavated appearance of the optic disc by ophthalmoscopy [2]. Locating and segmenting the optic disc (OD) is important in retinal image analysis. OD is the main landmark to establish retinal coordinate, and its dimensions and relative position with respect to other landmarks are sometimes used to calibrate measurements. OD analysis is used to determine the complexity of many diseases, most importantly, glaucoma. The disc can also be used as a starting point for CDR method [6]. Retinal fundus images provide an effective way to study and diagnose the health of optic nerve, vitreous, macula, retina, and blood vessels. In particular, the retinal blood vessels may provide important information about several system diseases, such as glaucoma, stroke, arteriosclerosis, arterial hypertension, heart diseases, and diabetic retinopathy. Early detection allows the patients to treat themselves before the disease can advance and avoid more serious complications, like tunnel vision or even total blindness, in case of diabetic retinopathy [3]. To identify the optic cup is important in the detection of glaucoma as the cup size is a complex and risk factor for glaucoma damage. However, automatic segmentation of the optic cup is challenging since the cup is defined as an excavation or depression in the optic disc which can be difficult to discern. We present an automated method for the detection of the optic cup boundary in non-stereo retinal fundus images based on the kinking of vessels [9]. We want to present the detection of glaucoma disease using cup to disc ratio (CDR).

## **2.MOTIVATION AND OBJECTIVES**

### **Motivation**

At present Glaucoma has been a major eye disease in the world. Many people are losing their eye sight because of Glaucoma. When an eye is affected by glaucoma, the eye is damaged for ever. Only proper treatment in time can minimizes the loss. Many research has been done to detect and diagnose the disease. Most of them are accurate and gives the result but none of them are 100% accurate. The research is going to be 97-98% accurate. As it is a serious disease and can damage the eye forever so it is urgent to detect earlier for cure. So we want to do a thesis such that it may detect the disease 100% accurately. We want to do this through optical cup to optical disc ratio image processing technique.

### **Objectives**

The main objective of this project is to analyse and diagnose the glaucoma using digital fundus images by using image processing technique.

- Detection and extraction of textures features and normalization of data.
- To localize and detect optic disk.
- To segment and extract the optic cup and optic disk.
- To find cup to disk ratio.
- To classify the images based on the features extracted using SVM classifier

The academic goal of this project is to develop the skill of research, MATLAB programming and analysis.

## **3.GLAUCOMA DETECTION**

**About Glaucoma:** Glaucoma is an ocular disorder characterized by the progressive degeneration of optic nerve fibres. Due to its lack of symptoms in its developing stages, and concurrent irreversibility once significant vision loss is detected, early detection of its onset is highly desirable if eventual blindness is to be avoided. While there has been work done on predicting glaucoma from other retinal image characteristics such as vessel distribution [1]. Glaucoma is the second leading cause of blindness worldwide. The retina is the innermost layer in the eye and the retinal nerve fibres transmit the visual signal from the photoreceptors in the eye to the brain via the bundle going out of the eye, known as the optic nerve. Glaucoma leads to continuous and speedy damage of the retinal nerve fibre layer and hence can lead to permanent blindness. The progression of the nerve fibre layer loss can be effectively stopped by treatment consisting of medication or surgery to reduce the intraocular pressure. Hence, the diagnosis of glaucoma at an earlier stage is very important for its treatment [27]. It is caused by irreversible damage of the optic nerve. As there is no cure for glaucoma, it is critical to diagnose glaucoma at an early stage to slow the progression. Digital colour fundus image has been widely used in recent years to diagnose various ocular diseases including glaucoma. The vertical Cup-to-Disc ratio (CDR), which is defined as the ratio of the vertical cup diameter over the vertical disc diameter, is an important indicator of glaucoma. It can be determined by marking the OD and optic cup in the fundus images. The OD, also known as the optic nerve head, is the location where the optic nerve connects to the retina. In a typical colour fundus image, the OD is an elliptic region which is brighter than its surroundings. The OD has an orange pink rim with a pale centre called the optic cup, which is a cup-like area devoid of neuro retinal tissue and normally white in colour. Quantitative analysis of the optic disc cupping can be used to evaluate the progression of glaucoma. As more and more optic nerve fibres die, the optic cup becomes larger with respect to the OD which corresponds to a larger vertical CDR [8].

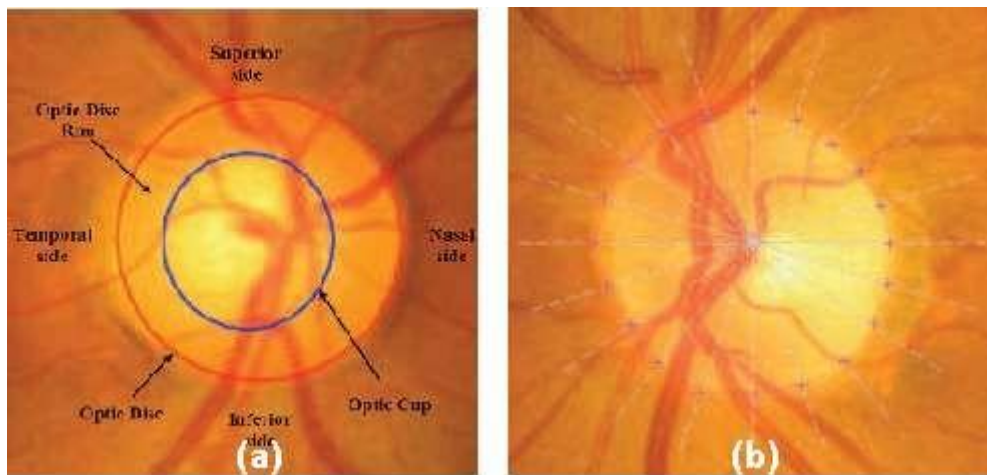


Figure 1:(a) Sample color fundus image with optic disc and cup highlighted; (b) Landmarks points in optic disc modeling.

However, glaucoma is often referred to as “The Silent Thief of Sight.” There is no cure of glaucoma yet, although it can be treated. Worldwide, it is the second leading cause of blindness. It affects one in two hundred people aged fifty years and younger, and one in ten over the age of eighty years. The damage to the optic nerve from glaucoma cannot be reversed. However, lowering the pressure in the eye can prevent further damage to the optic nerve and further peripheral vision loss. There are various types of glaucoma that can occur and progress without obvious symptoms or sign. Even there is no cure for glaucoma, early detection and prevention can avoid total loss of vision. Glaucoma can be divided into two main types, (1) Primary open angle glaucoma and (2) Angle closure glaucoma. Last but not least there is another glaucoma known as secondary glaucoma [29].

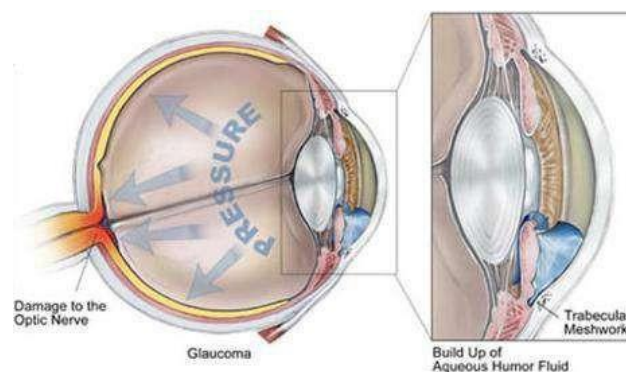


Figure 2: Glaucoma eye anatomy

#### 4.TYPES OF GLAUCOMA

Glaucoma is a group of eye diseases that can lead to blindness by damaging the optic nerve. The eye continuously produces a fluid, called the aqueous that must drain from the eye to maintain healthy eye pressure.

##### Primary Open Angle Glaucoma

The most common type of glaucoma is Primary Open Angle Glaucoma (POAG). In POAG, the eye's drainage canals become blocked, and the fluid accumulation causes pressure to build within the eye. This pressure can cause damage to the optic nerve, which transmits information from the eye to the brain [30].

This type of glaucoma is the most common (sometimes called as Chronic Glaucoma) and symptoms are slow to develop. As the glaucoma progress the side or peripheral vision is failing. It may cause a person to miss the objects out of the side or corner of the eye. It happens when the eye's drainage canals become clogged over time or the eye over-produces aqueous fluid which causes the pressure inside the eye to build

to abnormal levels. The inner eye pressure (IOP) rises because the correct amount of fluid can't drain out of the eye. It's affecting 70% to 80% of those who suffered from the disorder and accounts for 90% of glaucoma cases in the United States. It is painless and does not have acute attacks. It can develop gradually and go unnoticed, especially if caught early and treated [19].

### **Angle Closure Glaucoma**

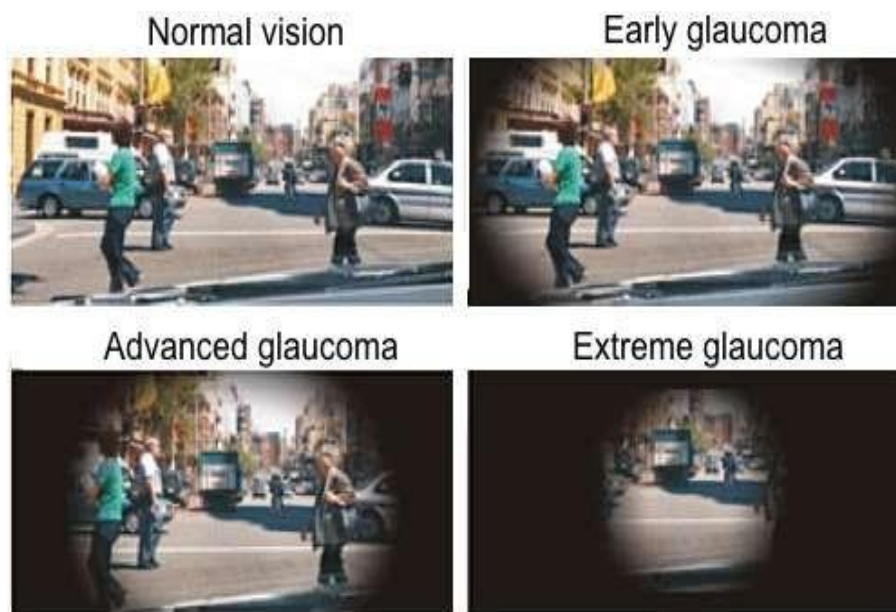Angle Closure Glaucoma is much less common than POAG in the United States. In this type of glaucoma, the aqueous cannot drain properly because the entrance to the drainage canal is either too narrow or is closed completely. In this case, eye pressure can rise very quickly and can be triggered by pupil dilation. Also known as Acute Narrow Angle Glaucoma and accounts for less than 10% of glaucoma cases in the United States. Although it is rare and different from open angle glaucoma, it is the most serious form of disease. The problem occurs more commonly in farsighted elderly people, particularly in women and often occurs in both eyes. Angle Closure Glaucoma occurs primarily in patients who have shallow space between the cornea at the front of the eye and the colour iris that lies just behind the cornea. As the eye ages, the pupil grows and become smaller, restricting the flow of fluid to the drainage site. As fluid builds up and blockage happens, a rapid rise in intraocular pressure can occur. This kind of Glaucoma is normally very painful because of the sudden increase in pressure inside in the eye. The symptoms of an acute attack are more severe and can be totally disable. They include severe pain, often accompanied by nausea and vomiting. Diabetes can be contributing cause to the development of glaucoma. Treatment of angle closure glaucoma is known as peripheral iridectomy and usually involves surgery to remove a small portion of the outer edge of the iris to allow aqueous fluid to flow easily to the drainage site [19].

### **Secondary Glaucoma**

Both open angle glaucoma and angle closure glaucoma can be primary or secondary conditions. Primary conditions are when the cause is unknown, unlike secondary conditions which can be traced to a known cause. Secondary glaucoma may be caused by a variety of medical conditions, medications, eye abnormalities and physical injuries. The treatment of secondary glaucoma is frequently associated to eye surgery [19]. Secondary glaucoma is those that develop as secondary to, or as complications of, other conditions such as eye trauma, cataracts, diabetes, eye surgery, or tumors. In many of these glaucoma, damage to the fluid drainage canal must be addressed with medication or surgery [30].

### **Normal Tension Glaucoma**

In this type of glaucoma, also called low-pressure glaucoma, the optic nerve is damaged even though the eye pressure is not excessively elevated. A family history of any type of glaucoma, cardiovascular disease, and Japanese ancestry are a few of the risk factors for this type of glaucoma. This type of glaucoma is treated much like POAG, but the eye pressure needs to be kept even lower to prevent progression of vision loss [30].



**Figure 3: The typical progression of vision loss from glaucoma.**

**Symptoms of glaucoma**

At first, open-angle glaucoma has no symptoms. It causes no pain. Vision stays normal. Glaucoma can develop in one or both eyes [31].

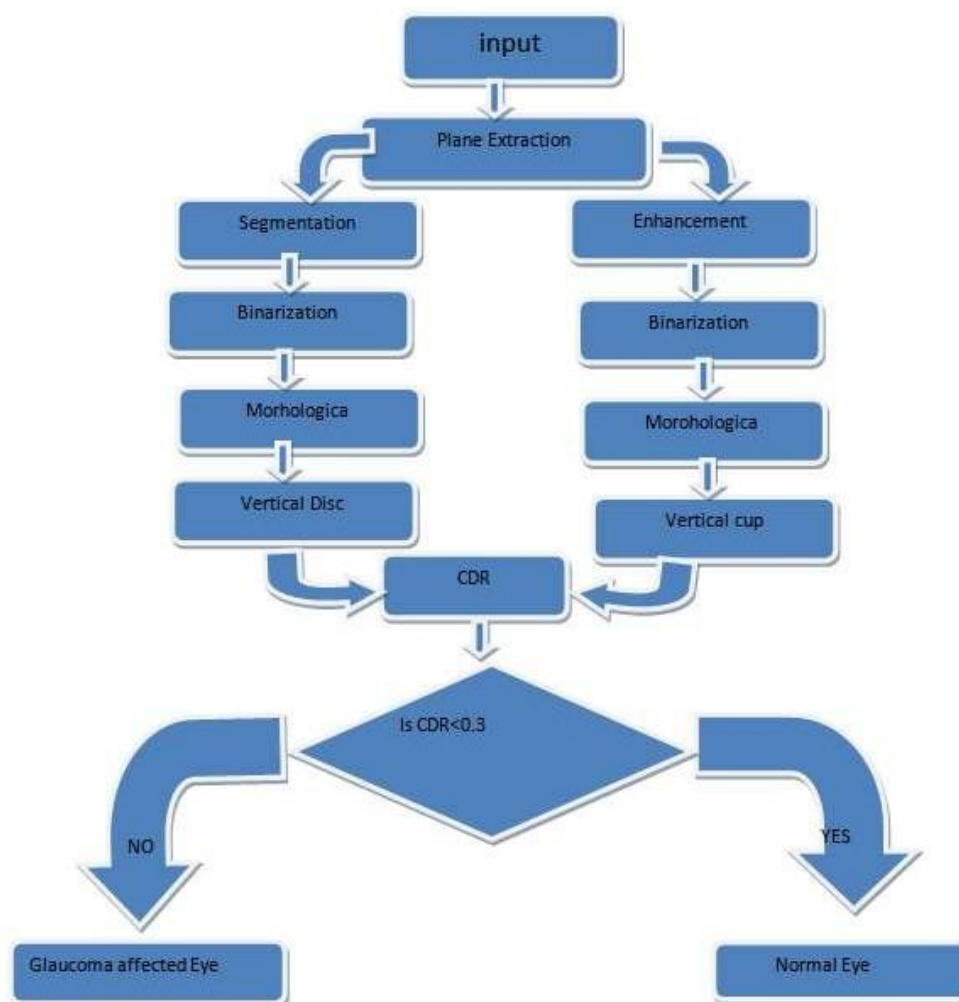
- Headaches
- Intense pain
- Blurred vision
- Nausea or Vomiting
- Medium dilation of the pupil
- Bloodshot eyes and increased sensitivity

However, in general the field of vision is being narrowed to such whereby one is unable to see clearly.

**5.PROPOSED METHOD**

**Image processing technique using cup to disc ratio (CDR):**

Glaucoma is an ocular condition whose progression leads to permanent blindness. Glaucoma is a chronic disease whose progression can only be stopped if detected accurately at an early stage. Proposed algorithm provides an automated glaucoma detection computer aided system using MATLAB software that enables the ophthalmologists in early diagnosis of glaucoma patients with high accuracy [17]. Algorithm takes a preprocessed fundus image and extracts optic cup and optic disc followed by CDR calculation. Intensity and textural features are extracted from the image to train and test the classifier. Result from glaucoma detection using CDR and features are combined to classify the image as glaucoma, non-glaucoma



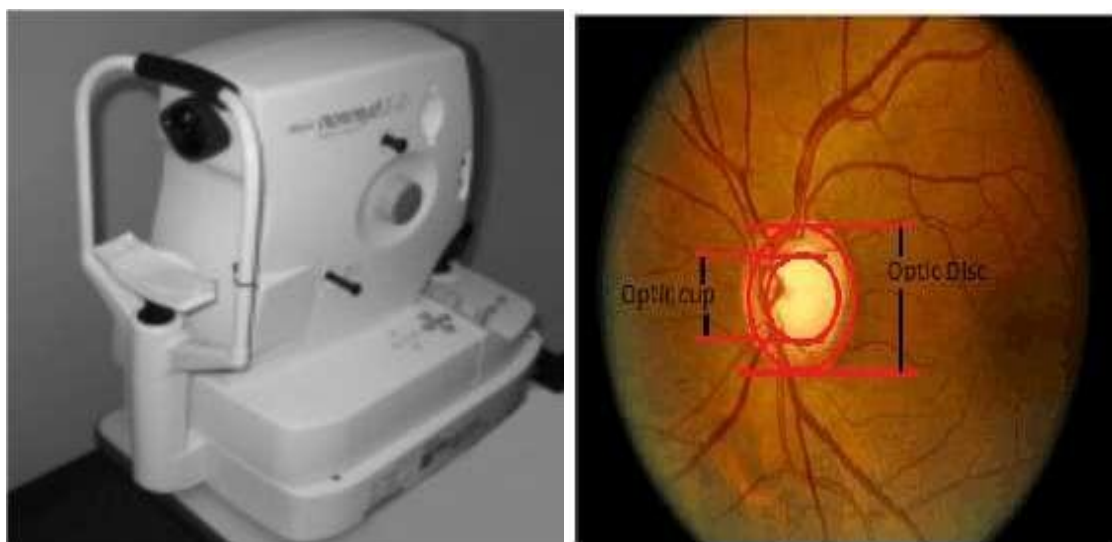
or suspect. Figure 4 depicts the complete methodology [33].

**Figure 4: Proposed Methodology.**

### **Image Acquisition**

Image acquisition is the foremost task of any image processing algorithm. The color fundus image used in the identification process is obtained by a fundus imager. This marks the first step of any processing. The particular goal in this step is to construct the image of the eye taken in a constrained and guided environment so as to make it readable to obtain the required information. Unless the image acquired is perfect, it becomes very difficult to analyze the image and come to a conclusion about the eye defect. Real time image acquisition is one method used to take images automatically by the device, process and file it for future analysis. Back ground image acquisition is another one common type of real time image acquisition. Digital imaging also helps in this process. It also supports in transmission of the data from one place to another [33]. Manual analysis of ophthalmic images is fairly time-consuming and accuracy depends on the expertise of the professionals. Automatic analysis of retinal images is an important tool. Automation aids in the detection, diagnosis, and prevention of risks associated with the disease. The fundus image is obtained from a fundus imager, or fundus camera which captures the inner view of the eye. The fundus image has a bright Centre region which is known as the nerve centre. This is the place where the nerves head forms. This is also called as the optic disc.

The innermost region of the optic disc is the optic cup as shown in figure 5



**Figure 5: Digital fundus camera and acquired retinal fundus image.**

### **Optic Disc detection and segmentation**

The interweaving of blood vessels is one of the major obstacles for accurate OD segmentation. Thus, a proper pre-processing is necessary to reduce the impact of blood vessels. For digital color fundus images, the red channel contains the least information about the blood vessels in the OD region and has the best contrast of OD with respect to the surrounding regions. Therefore, this channel is preferred in the model fitting process. However, in some images, the OD region cannot be identified through this channel because the intensity of this channel is evenly distributed. In such cases, an artificial image that is created by arithmetic operations on the green and blue components is used. In order to determine the best image to process, we define the image contrast ratio. Where is the mean intensity of all the pixels in the monochrome image, and is the standard deviation of all the pixel intensities [8].

Optic disc is a bright circular region in fundus image, thus Laplacian of Gaussian (LoG) is applied on the preprocessed padded image for its application in blob detection.

To make the LoG application process more efficient, it's application is done in frequency domain with an inverted LoG filter having a bright central peak to locate the blobs in the fundus image. Resulting image contains all the bright lesions detected as blobs. Morphological operations are performed to remove some unwanted noise. Image is segmented using a threshold value computed from the maximum intensity value in Gaussian kernelled image Gkm.

$$T = 0.6 \times Gkm.$$

Using the threshold value calculated in, 40% brightest pixels from the image are selected. In case of more than one bright region a screening is required to select the Optic disc region from non-optic disc region.

In our model, we choose 24 landmark points around the OD boundary with each pair of adjacent point forming an angle of 15 degrees with the OD center in order to build a robust PDM, we need to train the shape on a large training set. All the landmarked shape vectors should be aligned to each other by scaling, rotation and translation until the complete training set is properly aligned. The aim of aligning the training shapes is to minimize the weighted sum of squared.

### **Optic Cup detection and segmentation**

For optic cup segmentation, ground truth data is available only on the SEED-DB database. As a further comparison in addition to PBGC and PPF, we have implemented the reconstruction-based optic cup localization method with codebooks (RCN), as described in, which currently produces the best optic cup segmentations based on both absolute CDR error and NOR metrics, to the best of our knowledge. The reconstruction-based with codebooks method has been empirically demonstrated to strongly dominate the recent pixel, sliding window, threshold, r-bend and super pixel based approaches, as reported in and. Since reconstruction-based localization requires a prior optic disc segmentation, we provided it with both the ground truth disc segmentation (RCN-GTD), as well as the CNN-FE disc segmentation (RCN-CD), to check for consistency and to simulate real-world operation.

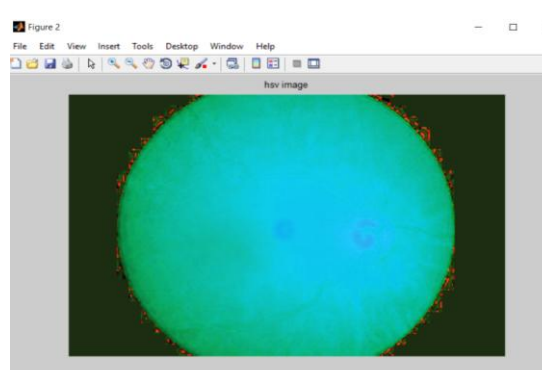
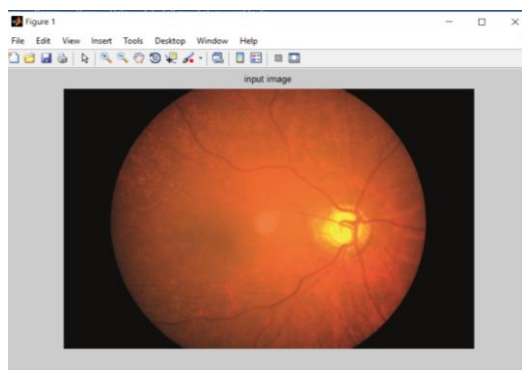
We have also taken care to search for an optimal regularization weight, and found that performance is maximized at  $\lambda = 70000$  on both the absolute CDR error and NOR metrics. The results for optic cup NOR, and for the absolute CDR error. For all methods, the three images (1.3% of the total) rejected due to having segmentation noise  $N \geq 1$  were ignored in calculating the results. We observe that CNN-FE offers a considerable improvement over the reconstruction-based, physiologically plausible features and prior-based graph-cut methods, on both the optic cup NOR and absolute CDR error metrics. The relative improvement of CNN-FE against RCN-CD, PPF and PBGC are 14.2%, 40.9% and 65.5% on the absolute CDR error metric, and 13.7%, 28.7% and 65.2% on the NOR metric respectively [9].

### **CDR calculation**

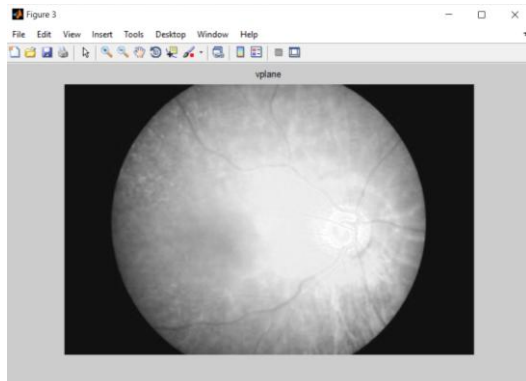
In ophthalmology, retinal imaging and its processing plays a very important role in detecting diseases like glaucoma and diabetic retinopathy. These are abnormalities formed in the eye or ocular region. Glaucoma being the main cause of blindness all around the world is accounted as 13% of the population [33]. This is caused by the damage of the optic nerve cells. These patients contribute to the whole account of visually challenged people. The visual damage may also be due to changes in the optic nerve head. Glaucoma identification is made easy by calculating the optic disc and cup ratio. This neuro retinal CDR value is deciding factor of glaucoma. As this value increases, the severity of the disease increases. At present this calculation has been done manually by experienced ophthalmologist. This is because the blood vessel that surrounds the optic disc makes it very difficult to be segmented, thus making it very difficult to obtain the cup to disc ratio. The process does not stop with the cup disc segmentation various other features can also be obtained from the retinal images. In this we concentrate on the vertical cup to disc ratio only. As emphasized this ratio is a very important index in identification of glaucoma.

$$CDR = (OD \text{ area} / OC \text{ area}) * 2.$$

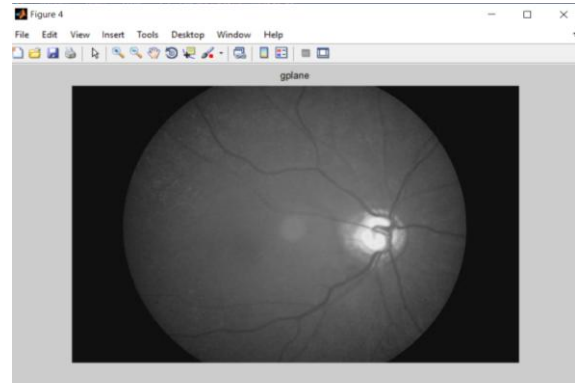
## **6. SIMULATION RESULTS AND DISCUSSION**



(a)



(b)

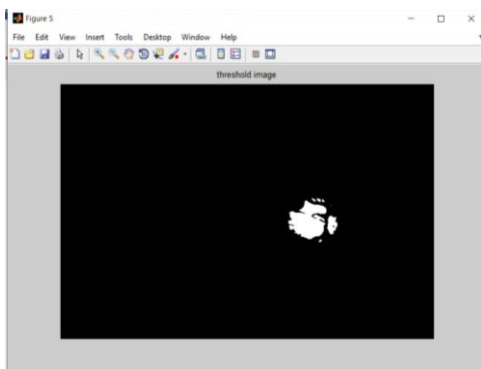


(c)

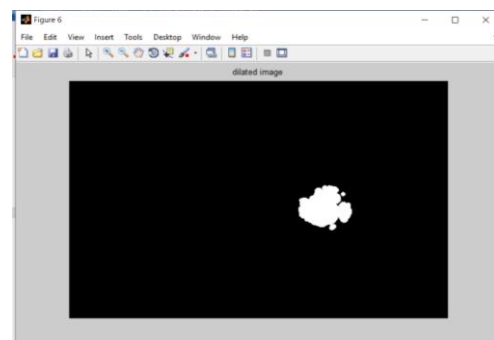
(d)

(a) Input image (b) hsv image (c) V palne from hsv (d) g plane from rgb (input).

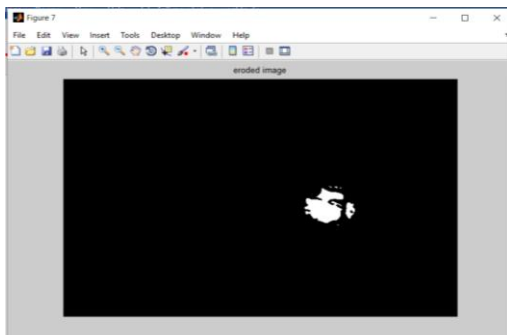
Optic Cup extraction:



(a)



(b)



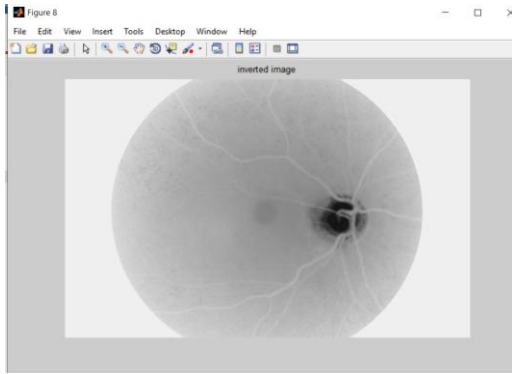
(c)

**(a) Thresholded image (b) Dilated image (c) Eroded image.**

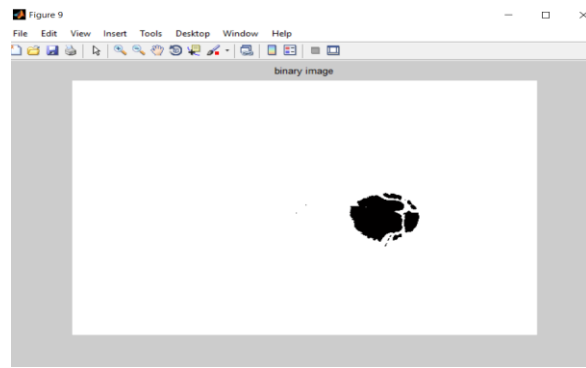
- Area of Cup = Number of White Pixels in thresholded Image.

Optic Disc Extraction:

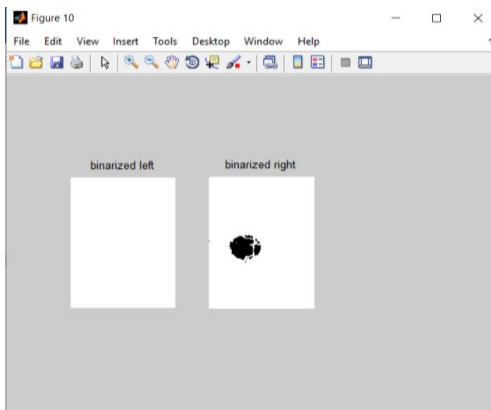




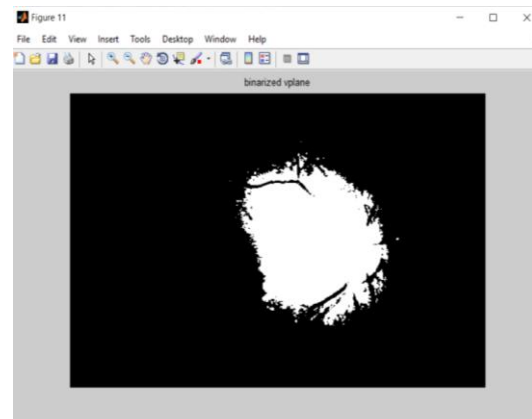
(a)



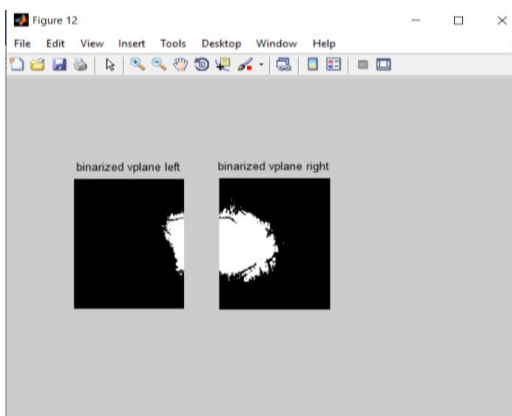
(b)



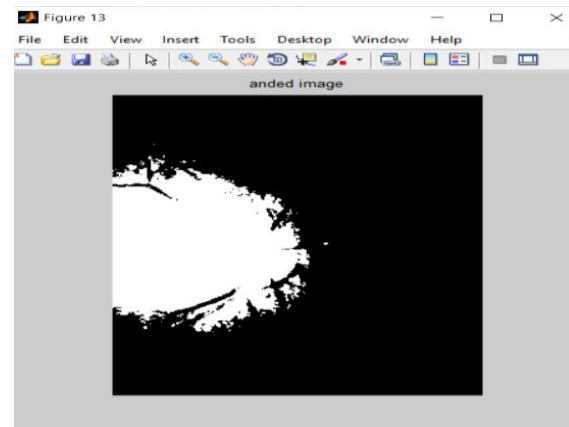
(c)



(d)




(e)



(f)

**(a) Inverted g Plane (b) Binarized g Plane (c) Left and Right Parts of Binarized g Plane (d) Binarized v Plane (e) Left and Right Parts of Binarized v Plane (f) ANDed Image.**

- Area of Disc = Number of White Pixels in ANDed Image.
- $CDR = (\text{Area of Cup} / \text{Area of Disc})$ .



## 7. CONCLUSION AND FUTURE SCOPE

In this paper, it is concluded that for detection and diagnosis of glaucoma, there are multiple medical tests available, but on behalf of some tests image processing techniques are applied on the retinal fundus images and getting more accurate result through it. A computer based system for detection of glaucoma abnormal eyes through fundus images is developed algorithm using image processing techniques, Cup to Disc Ratio (CDR) and SVM classifier. The features are computed automatically and this gives us a high degree of accuracy. These features were tested by using Student T-Test, which showed that all CDR features are clinically significant. The system, we propose can identify the presence of glaucoma to the accuracy of 95.9%. Another proposed method of this work is to combine the features into an integrated index in such a way that its value is distinctly different for normal and glaucoma subjects. However, early detection is important to prevent the progression of the disease. Results showed that patient having High BP and Diabetes and high myopia and high IOP and also having family history of this disease are more prone to glaucoma. It is also dependent on age factor; it was found that the people having age above 50 are more prone to this disease [11]. The results are promising for a population based study with images with multiple pathologies which indicates that there is good potential for our method to aid the diagnosis of glaucoma.

## 8. REFERENCES

- [1]. Gilbert Lim, Yuan Cheng, Wynne Hsu, Mong Li Lee, "Integrated Optic Disc and Cup Segmentation with Deep Learning", 2015 IEEE 27th International Conference on Tools with Artificial Intelligence.
- [2]. Harry A Quigley, "Number of people with glaucoma worldwide", British Journal of Ophthalmology 1996; 80: 389-393
- [3]. Jardel Rodrigues, Nivando Bezerra, "Retinal Vessel Segmentation Using Parallel Grayscale Skeletonization Algorithm and Mathematical Morphology", 2016 29th SIBGRAPI Conference on Graphics, Patterns and Images.
- [4]. Mircea Mujat, PhD, "High-resolution retinal imaging –visualizing cellular structures in the living eye", Boston Chapter of the IEEE Photonics Society.
- [5]. John A. Lusk and Brian Nutter, "Automated 3-D Reconstruction of Stereo Fundus Images via Camera Calibration and Image Rectification", 2009 IEEE.
- [6]. Andrea Giachetti, Lucia Ballerini, Emanuele Trucco, "Accurate and reliable segmentation of the optic disc in digital fundus images", Journal of Medical Imaging 1(2), 024001 (Jul-Sep 2014).
- [7]. Dr. PSJ Kumar, Ms. Sukanya Banerjee, "A Survey on Image Processing Techniques for Glaucoma Detection", International Journal of Advanced Research in Computer Engineering & Technology (IJARCET) Volume 3 Issue 12, December 2014.
- [8]. Fengshou Yin, Jiang Liu, Damon Wing Kee Wong, NganMeng Tan, Carol Cheung, Mani Baskaran, Tin Aung and Tien Yin Wong, "Automated Segmentation of Optic Disc and Optic Cup in Fundus Images for Glaucoma Diagnosis", IEEE 2012.
- [9]. Damon W.K. Wong, Jiang Liu, Ngan-Meng Tan, Fengshou Yin, Beng-Hai Lee, "Detecting the optic cup excavation in retinal fundus images by automatic detection of vessel kinking", 21st International Conference on Pattern Recognition (ICPR 2012) November 11- 15, 2012. Tsukuba, Japan.
- [10]. Attila Budai, Andre Aichert, Bronislav Vymazal, Joachim Hornegger, Georg Michelson, "Optic Disk Localization using Fast Radial Symmetry Transform", 2013 IEEE.
- [11]. Kavita Choudhary, Sonia Wadhwa, "Glaucoma Detection using Cross Validation Algorithm", 2014 Fourth International Conference on Advanced Computing & Communication Technologies.
- [12]. Anum Abdul Salam, M. Usman Akram, Member, IEEE, Sarmad Abbas, Syed M. Anwar, "Optic Disc Localization using Local Vessel Based Features and Support Vector Machine", IEEE
- [13]. Anum Abdul Salam, Usman Akram, Kamran Wazir, Syed Muhammad Anwar, Muhammad Majid, "Autonomous Glaucoma Detection from Fundus Image Using Cup to Disc Ratio and Hybrid Features", 2015 IEEE International Symposium on Signal Processing and Information Technology (ISSPIT).

- [14]. Ashi Agarwal, Ashish Issac, Anushikha Singh, Malay Kishore Dutta, "Automatic Imaging Method for Optic Disc Segmentation using Morphological Techniques and Active Contour Fitting", IEEE, 2015, 15th international conference on bioinformatics and bioengineering.
- [15]. Hui-Huang Hsu, Ashmita Gupta, Ashish Issac, Malay Kishore Dutta, "Adaptive Thresholding For Skin Lesion Segmentation Using Statistical Parameters", 2017 31st International Conference on Advanced Information Networking and Applications Workshops.
- [16]. Mohammed Mahdi Abdul, Clare Chandler and Clare Gilbert, "Glaucoma, 'the silent thief of sight': patients' perspectives and health seeking behaviour in Bauchi, northern Nigeria", Abdull et al. BMC Ophthalmology (2016) 16:44 DOI 10.1186/s12886-016-0220-6.
- [17]. Hafsa Ahmad, Abubakar Yamin, Aqsa Shakeel, Syed Omer Gillani, Umer Ansari, "Detection of Glaucoma Using Retinal Fundus Images", 2014 International Conference on Robotics and Emerging Allied Technologies in Engineering (iCREATE) Islamabad, Pakistan, April 22-24, 2014.
- [18]. Anum A. Salam, Tehmina Khalil, M. Usman Akram, Amina Jameel and Imran Basit, "Automated detection of glaucoma using structural and non-structural features", Salam et al. Springer Plus (2016) 5:1519 DOI 10.1186/s40064-016-3175-4.
- [19]. Pei-Xia Wu, Wen-Yi Guo, Hai-Ou Xia, Hui-Juan Lu & Shu-Xin Xi, "Patients' experience of living with glaucoma: a phenomenological", JJOJAN: ORIGINAL RESEARCH.
- [20]. Dnyaneshwari D. Patil, Ramesh Manza, Ph.D., Gangadevi C. Bedke, "Diagnose Glaucoma by Proposed Image Processing Methods", International Journal of Computer Applications (0975 – 8887) Volume 106 – No.8, November 2014.
- [21]. Aliaa Abdel-Haleim Abdel-Razik Youssif, Atef Zaki Ghalwash, and Amr Ahmed Sabry Abdel-Rahman Ghoneim, "Optic Disc Detection From Normalized Digital Fundus Images by Means of a Vessels' Direction Matched Filter", AIEEE TRANSACTIONS ON MEDICAL IMAGING, VOL. 27, NO. 1, JANUARY 2008.
- [22]. Jeffrey Wigdahl, Pedro Guimaraes, Alfredo Ruggeri, "A shortest path approach to optic disc detection in retinal fundus images", Journal for Modeling in Ophthalmology 2016; 4:29-42 Original article.
- [23]. Mishra Madhusudhan, Nath Malay, S.R. Nirmala, and Dandapat Samerendra, "Image Processing Techniques for Glaucoma Detection", Conference Paper in Communications in Computer and Information Science · July 2011.
- [24]. Michael D. Abramoff [Senior Member, IEEE], Mona K. Garvin [Member, IEEE], Milan Sonka [Fellow, IEEE], "Retinal Imaging and Image Analysis", IEEE Trans Med Imaging. 2010 January 1; 3: 169–208. doi:10.1109/RBME.2010.2084567.
- [25]. Muhammad Abdullah, Muhammad Moazam Frazand Sarah A. Barman "Localization and segmentation of optic disc in retinal images using circular Hough transform and grow-cut algorithm", Abdullah et al. (2016), PeerJ, DOI 10.7717/peerj.2003.f advanced nursing
- [26]. Michael D. Abramoff [Senior Member, IEEE], Mona K. Garvin [Member, IEEE], Milan Sonka [Fellow, IEEE], "Retinal Imaging and Image Analysis", IEEE Trans Med Imaging. 2010 January 1; 3: 169–208.
- [27]. The International Bank for Reconstruction and Development/the World Bank: World Development Report 1993. Oxford: Oxford University Press, 1993.
- [28]. Milan Sonka [Fellow, IEEE], Michael D. Abramoff [Senior Member, IEEE], Mona K. Garvin [Member, IEEE], Retinal Imaging and Image Analysis.
- [29]. Programme for the Prevention of Blindness and Deafness, World Health Organization, Geneva 1211, Switzerland. resnikoffs@who.int. "Global data on visual impairment in the year 2002"
- [30]. "Eye health, Anatomy of eye" available on-line at <http://www.visionaware.org/info/your-eye-condition/eyehealth/anatomy-of-the-eye/12>
- [31]. "National Eye Institute (NEI)" available on-line at [https://nei.nih.gov/health/glaucoma/glaucoma\\_facts](https://nei.nih.gov/health/glaucoma/glaucoma_facts)
- [32]. "Glaucoma Research Foundation" available on-line at <https://www.glaucoma.org/glaucoma/diagnostic-tests.php>
- [33]. "Allied academies, Biomedical Research" available on-line at <http://www.alliedacademies.org/articles/robust-cdr-calculation-for-glaucoma-identification-7909.html>
- [34]. Mayo Clinic, Mayo Foundation for Medical Education and Research, available on-line at <https://www.mayoclinic.org/diseases-conditions/glaucoma/symptoms-causes/syc-20372839>
- [35]. A. Murthi & M. Madheswaran 'Enhancement Of Optic Cup To Disc Ratio Detection In Glaucoma Diagnosis' 978-14577-1583-9/12/\$26.00 © 2012 IEEE
- [36]. Li Xiong, Huiqi Li and Yan Zheng 'Automatic Detection of Glaucoma in Retinal Images' 978-1-4799-43159/14/\$31.00\_c 2014 IEEE.
- [37]. Mei-Ling Huang, Hsin-Yi Chen, Jian-Jun Huang: "Glaucoma detection using adaptive neuro-fuzzy inference system", Expert Systems with Applications 32 (2007) 458-468.

- [38]. JyotikaPruthi, Dr.Saurabh Mukherjee: "Computer Based Early Diagnosis of Glaucoma in Biomedical Data Using Image Processing and Automated Early Nerve Fiber Layer Defects Detection using Feature Extraction in Retinal Colored Stereo Fundus Images", International Journal of Scientific & Engineering Research, Volume 4, Issue 4, April 2013.
- [39]. Vicente Grau, J. Crawford Downs, and Claude F. Burgoyne, "Segmentation Of Trabeculated Structures Using An Anisotropic Markov Random Field: Application To The Study Of The Optic Nerve Head In Glaucoma", IEEE Transactions on Medical Imaging, Vol. 25, No. 3, March 2006. Pg.: 245
- [40]. Inoue, Kenji Yanashima, Kazushige Magatani, TakuroKurihara, Naoto, "Development Of A Simple Diagnostic Method For The Glaucoma Using Ocular Fundus Pictures", in the Proceedings of the 2005 IEEE Engineering in Medicine and Biology 27th Annual Conference Shanghai, China, September